








Oral manifestation of syphilis

Manifestación oral de la sífilis

Thais Aquino Moreira de Sousa¹  , Juliana Syndia Silva Santos¹ , Fabiana Moura da Motta Silveira¹ , Luciana Silva Regueira¹ , Maria Gabriela Lima Barbosa Monteiro¹ , Betânia Ferreira Lima de Oliveira Gonçalves¹ 

¹ Institute of Integral Medicine Prof Fernando Figueira, Dentistry Department, Hospital Dentistry Residence Program. Recife, Brazil.



Cómo citar: Aquino Moreira de Sousa T, Silva Santos JS, Moura da Motta Silveira F, Silva Regueira L, Lima Barbosa Monteiro MG, Ferreira Lima de Oliveira Gonçalves B. **Oral manifestation of syphilis.** Rev Cubana Estomatol. 2021;58(2):e3029

ABSTRACT

Introduction: syphilis is a sexually transmitted disease with an annual incidence of 12 million people worldwide. In Brazil, there are increasing rates of infant mortality and incidence due to this disease. **Objective:** to report a case of primary syphilis with manifestation in the mouth. **Case report:** patient 50-years-old, male, homosexual with a complaint of an asymptomatic lesion on the lower left lip for about 2 months. In the intraoral physical examination, it was observed ulcerated lesion, with white-yellowish pseudomembrane, non-suppurative with hardened, elevated and badly-delimited edges measuring approximately 3 cm on the lower left lip. An incisional biopsy of the lesion was carried out and it was prescribed high doses of prednisolone, but without success. During follow-up, erythematous lesions target-shaped appeared in the palmar region and the resulting histopathological report showed ulcerated lichenoid cheilitis. Hematological exams confirmed positive for syphilis in the VDRL test. The treatment was penicillin G benzathine for 3 weeks. **Conclusions:** in the present case, the syphilitic lesion has clinical characteristics common to other diseases. Thus, dentists should know their clinical manifestations, that would aid in early diagnosis and treatment.

Keywords: sexually transmitted diseases; syphilis; mouth.

RESUMEN

Introducción: La sífilis es una enfermedad de transmisión sexual con una incidencia anual de 12 millones de personas en el mundo. En Brasil, hay crecientes tasas de incidencia y mortalidad infantil por esa enfermedad. **Objetivo:** Describir un caso de sífilis primaria con manifestación en cavidad oral. **Presentación del caso:** Paciente masculino de 50 años de edad, homosexual, con queja de lesión sin dolor en el labio inferior izquierdo que había comenzado aproximadamente dos meses antes de asistir a la consulta. En la inspección clínica intraoral se observó lesión ulcerada, que medía aproximadamente 3 cm en el labio inferior izquierdo, con seudomembrana blanco-amarillenta, no supurativa, con bordes indurados, elevados y mal delimitados. Se tomó una biopsia de la lesión y se prescribieron altas dosis de prednisolona, pero sin éxito. Durante el seguimiento, lesiones eritematosas en “tiro al blanco” aparecieron en la región palmar y el estudio histopatológico reveló queilitis liquenoide ulcerada. Los exámenes hematológicos confirmaron positividad para sífilis en la prueba VDRL. El tratamiento fue penicilina G benzatínica por tres semanas. **Conclusiones:** En el presente caso la lesión sífilítica tenía características clínicas comunes a otras enfermedades. Por lo tanto, los dentistas deben conocer sus manifestaciones clínicas, que ayudarían en el diagnóstico y tratamiento tempranos.

Palabras clave: enfermedades de transmisión sexual; sífilis; boca.



Este es un artículo en Acceso Abierto distribuido según los términos de la Licencia *Creative Commons* Atribución- No Comercial 4.0 que permite el uso, distribución y reproducción no comerciales y sin restricciones en cualquier medio, siempre que sea debidamente citada la fuente primaria de publicación.

<http://www.revestomatologia.sld.cu/index.php/est/article/view/3029>

INTRODUCTION

Syphilis is a sexually transmitted disease represented clinically for four stages of disease evolution: primary, secondary, of latency and tertiary. The World Health Organization (WHO) estimated an annual incidence of syphilis of 12 million.⁽¹⁾ In Brazil, it has been increasing the number of cases of syphilis in pregnant women, congenital and acquired over the last years.⁽²⁾

According to the syphilis phase, lesions present different manifestations and may affect different organs, including the mouth, although this is unusual. Therefore, dentist should be capable to diagnose syphilis on its early stages and assist the beginning of the treatment quickly.

This paper aims to report a case of primary syphilis with mouth manifestation.

CASE REPORT

Patient 50-years-old, male, homosexual, smoker, and alcoholic with a complaint of an asymptomatic lesion on the lower left lip for about 2 months. The lesion appeared as a white stain on the lower lip, becoming ulcerated within approximately 10 days. Initially, it was diagnosed as aphthous and treated with topical application of triamcinolone acetonide. After 1 month, the lesion persisted. A new dental evaluation observed dental veneer's contact with the affected area. So the lichenoid reaction was suspected. Adjustment of the incisal dental veneers was performed, but with no lesion remission.

Due to the persistence of lesions, the patient sought a stomatologist. In the intraoral physical examination, it was observed ulcerated lesion with white-yellowish pseudomembrane, non-suppurative, with hardened, elevated and badly-delimited borders, measuring approximately 3 cm on the lower left lip (Fig. 1).



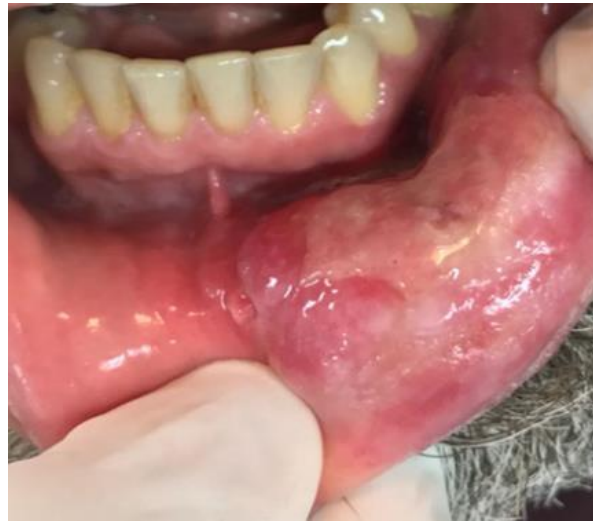

Fig. 1 - Ulcerated lesion with white-yellowish pseudomembrane on the lower left lip after 2 months of evolution.

Squamous cell carcinoma and lichenoid reaction were considered as diagnostic hypotheses. An incisional biopsy of the lesion was carried out and the patient was sent to dermatology to treat the hypothesis of lichenoid reaction with high doses of prednisolone for 21 days.

During follow-up, there were no clinical changes of the lesion in response to prednisolone, however erythematous lesion target-shaped in the palmar region appeared (Fig. 2). Hematological exams confirmed positive for syphilis in the VDRL test and HIV negativity. For treatment, the dermatologist recommended weekly applications of benzathine penicillin G for 3 weeks. Two months after initiation of antibiotic therapy, the patient returned to dental service with regression of lesion in the mouth, but with scar tissue on the affected area (Fig. 3).



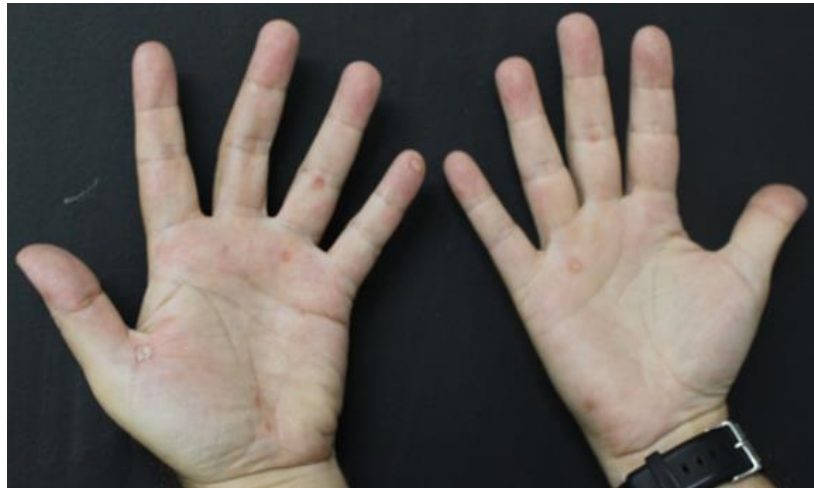

Fig. 2 - Target erythematous spots in hands.

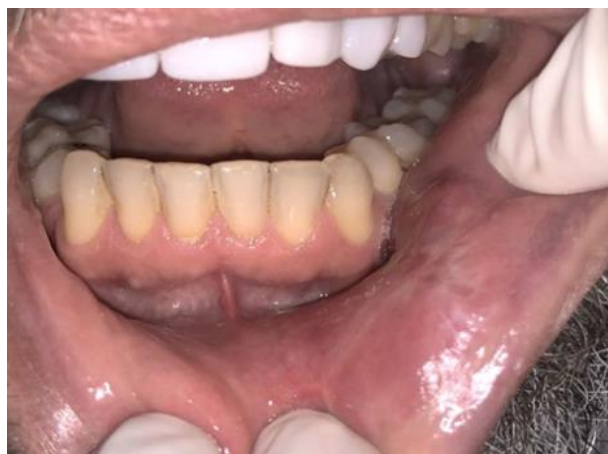

Fig. 3 - Scar tissue after 2 months of initiation of treatment.

DISCUSSION

Primary syphilis is characterized by a solitary papula lesion that develops central ulceration, known as a chancre. Oral lesions are uncommon if left untreated, the disease progresses to secondary syphilis.⁽¹⁾ In this stage has generalized mucocutaneous lesions affecting the palms and soles.⁽³⁾ If the signs and symptoms disappear, the patient enters a latency phase, that may last for years. Some cases of latent syphilis can be changed to tertiary syphilis, which is characterized by the most serious complications of the disease.^(1,4)



Este es un artículo en Acceso Abierto distribuido según los términos de la Licencia *Creative Commons* Atribución- No Comercial 4.0 que permite el uso, distribución y reproducción no comerciales y sin restricciones en cualquier medio, siempre que sea debidamente citada la fuente primaria de publicación.

<http://www.revestomatologia.sld.cu/index.php/est/article/view/3029>

It was observed acquired syphilis in the primary phase on the mouth, evolving to secondary syphilis due to the appearance of lesions in the hands. Acquired syphilis occurs more frequently in men (59.8 %), whites (39.1 %) and aged between 20-29 years (32.3 %).⁽³⁾ The study is similar to literature, except for the age, because this patient was 50 years old.

Oral involvement by syphilis may resemble different types of lesions, including squamous cell carcinoma, lichenoid reaction and erythema multiforme.^(4,5,6) Syphilis can be associated with HIV and both of them are usually present in homosexual patient.^(5,7,8) In this study, the patient was homosexual and negative for HIV.

Diagnosis for syphilis is confirmed by direct detection methods, an examination of cerebrospinal fluid and serological tests, including the Laboratory of Venereal Disease Research (VDRL).^(1,9,10) The main treatment uses penicillin, which dose and schedule vary according to the stage of the disease and its repercussions on the health of the patient.^(4,9,10)

Syphilis is an infectious systemic preventable disease with diagnosis and treatment already established around the world. However, the consequences of non-treatment can be severe. The case report of syphilis from an oral lesion represents fundamental participation of dentists in the diagnosis and early treatment.

REFERENCES

1. Andrade ALMB, Magalhães PVVS, Moraes MM, Tresoldi AT, Pereira RM. Late diagnosis of congenital syphilis: a recurring reality in women and children health care in Brazil. *Brazilian Journal of Pediatrics*. 2018;36(3):376-81. DOI: [10.1590/1984-0462/2018;36;3;00011](https://doi.org/10.1590/1984-0462/2018;36;3;00011)
2. Bjekić M, Marković M, Šipetić S. Clinical manifestations of primary syphilis in homosexual men. *Brazilian Journal of Infectious Diseases*. 2012;16(4):387-9. DOI: [10.1016/j.bjid.2012.06.013](https://doi.org/10.1016/j.bjid.2012.06.013)
3. Safe IP, Maia DCC. Secondary syphilis with oral manifestation. *Brazilian Journal of Infectious Diseases*. 2014;18(1):95. DOI: [10.1016/j.bjid.2013.06.003](https://doi.org/10.1016/j.bjid.2013.06.003)
4. de Paulo LFB, Servato JPS, Oliveira MTF, Durighetto Jr AF, Zanetta-Barbosa D. Oral manifestations of secondary syphilis. *International Journal of Infectious Diseases*. 2015;35:40-2. DOI: [10.1016/j.ijid.2015.04.007](https://doi.org/10.1016/j.ijid.2015.04.007)
5. Liu XK, Li J. Secondary syphilis-related oral mucous patches. *IDCases*. 2017;9:34-5. DOI: [10.1016%2Fj.idcr.2017.04.015](https://doi.org/10.1016%2Fj.idcr.2017.04.015)
6. Seibt CE, Munerato MC. Secondary syphilis in the oral cavity and the role of the dental surgeon in STD prevention, diagnosis and treatment: a case series study. *Brazilian Journal of Infectious Diseases*. 2016;20(4):393-8. DOI: [10.1016/j.bjid.2016.03.008](https://doi.org/10.1016/j.bjid.2016.03.008)
7. Nissanka-Jayasuriya EH, Odell EW, Phillips C. Dental stigmata of congenital syphilis: a historic review with present day relevance. *Head and Neck Pathology*. 2016;10:327-31. DOI: [10.1007/s12105-016-0703-z](https://doi.org/10.1007/s12105-016-0703-z)
8. Viñals-Iglesias H, Chimenos-Küstner E. The reappearance of a forgotten disease in the oral cavity: syphilis. *Medicina Oral, Patología Oral y Cirugía Bucal*. 2009 [access: 02/05/2019];14(9):416-20. Available in: <http://diposit.ub.edu/dspace/handle/2445/48465>



9. Carvalho S, Sanches M, Velho GC, Alves R, Selores M. Major Multiforme Erythema with Sertraline. Journal of the Portuguese Society of Dermatology and Venereology. 2015;73(3):393-6. DOI: [10.29021/spdv.73.3.465](https://doi.org/10.29021/spdv.73.3.465)

10. Strieder L, León JE, Carvalho YR, Kaminagakura E. Oral syphilis: report of three cases and characterization of the inflammatory cells. Annals of diagnostic pathology. 2015;19:76-80. DOI: [10.1016/j.anndiagpath.2015.01.003](https://doi.org/10.1016/j.anndiagpath.2015.01.003)

CONFLICT OF INTEREST

The authors of manuscript entitled “Oral manifestation of syphilis” certify that they have no affiliations with or involvement in any organization or entity with any financial interest (such as honoraria; educational grants; participation in speakers’ bureaus; membership, employment, consultancies, stock ownership, or other equity interest; and expert testimony or patent-licensing arrangements), or non-financial interest (such as personal or professional relationships, affiliations, knowledge or beliefs) in the subject matter or materials discussed in this manuscript.

CONTRIBUTIONS OF THE AUTHORS

Thais Aquino Moreira de Sousa: wrote the manuscript.

Juliana Syndia Silva Santos: wrote the manuscript.

Fabiana Moura da Motta Silveira: proofread the manuscript.

Luciana Silva Regueira: proofread the manuscript.

Maria Gabriela Lima Barbosa Monteiro: contributed substantially to discussion.

Betânia Ferreira Lima de Oliveira Gonçalves: contributed substantially to discussion.

Recibido: 26/08/2019

Aceptado: 16/12/2019

Publicado: 29/02/2021



Este es un artículo en Acceso Abierto distribuido según los términos de la Licencia *Creative Commons* Atribución- No Comercial 4.0 que permite el uso, distribución y reproducción no comerciales y sin restricciones en cualquier medio, siempre que sea debidamente citada la fuente primaria de publicación.

<http://www.revestomatologia.sld.cu/index.php/est/article/view/3029>